

A novel *PITX2* mutation in non-syndromic orodental anomalies

N Intarak¹ | T Theerapanon² | C Ittiwut^{3,4} | K Suphapeetiporn^{3,4}  | T Porntaveetus¹  | V Shotelersuk^{3,4}

¹Craniofacial Genetics and Stem Cells Research Group, Department of Physiology, Faculty of Dentistry, Chulalongkorn University, Bangkok, Thailand

²Excellence Center in Regenerative Dentistry, Faculty of Dentistry, Chulalongkorn University, Bangkok, Thailand

³Center of Excellence for Medical Genetics, Department of Pediatrics, Faculty of Medicine, Chulalongkorn University, Bangkok, Thailand

⁴Excellence Center for Medical Genetics, King Chulalongkorn Memorial Hospital, The Thai Red Cross Society, Bangkok, Thailand

Correspondence

Thanrira Porntaveetus, Department of Physiology, Faculty of Dentistry, Chulalongkorn University, Bangkok, Thailand. Email: thanrira.p@chula.ac.th

Funding information

Thailand Research Fund (TRF) and Office of Higher Education Commission (OHEC) Thailand, Grant/Award Number: MRG6080001; the Faculty of Dentistry, Chulalongkorn University, Grant/Award Number: DRF60007; Chulalongkorn Academic Advancement Into Its 2nd Century Project, the Ratchadapisek Sompoch Endowment Fund

Objective: To identify orodental characteristics and genetic aetiology of a family affected with non-syndromic orodental anomalies.

Subjects and Methods: Physical and oral features were characterised. DNA was collected from an affected Thai family. Whole-exome sequencing was employed to identify the pathogenic variants associated with inherited orodental anomalies. The presence of the identified mutation was confirmed by Sanger sequencing.

Results: We observed unique orodental manifestations including oligodontia, retained primary teeth, taurodont molars, peg-shaped maxillary central incisors, high attached frenum with nodule and midline diastema in the proband and her mother. Mutation analyses revealed a novel heterozygous frameshift deletion, c.573_574delCA, p.L193QfsX5, in exon 5 of *PITX2A* in affected family members. The amino acid alterations, localised in the transcriptional activation domain 2 in the C-terminus of *PITX2*, were evolutionarily conserved. Mutations in *PITX2* have been associated with autosomal-dominant Axenfeld-Rieger syndrome and non-syndromic eye abnormalities, but never been found to cause isolated oral anomalies.

Conclusions: This study for the first time demonstrates that the *PITX2* mutation could lead to non-syndromic orodental anomalies in humans. We propose that the specific location in the C-terminal domain of *PITX2* is exclusively necessary for tooth development.

KEYWORDS

agenesis, genetics, isolated, tooth

1 | INTRODUCTION

Orodental anomalies are groups of conditions with developmental disturbances of teeth, and oral soft and hard tissues. It is a genetically and phenotypically heterogeneous condition, which can be syndromic or non-syndromic, and can be influenced by both genetic and environmental factors. Tooth agenesis, a prevalent orodental anomaly, has been associated with mutations in several genes including *MSX1*, *PAX9*, *EDA*, *AXIN2* and *WNT10A* (van den Boogaard et al., 2012; Nieminen, 2009).

The paired-like homeodomain transcription factor 2 (*PITX2*; OMIM 601542), located at 4q25, is a member of the bicoid/paired-related

homeodomain family of transcriptional factors that plays an important role in the development of various tissues including the eyes, heart, brain, limb, umbilicus and teeth (Hjalt, Semina, Amendt, & Murray, 2000; Lin et al., 1999; Semina et al., 1996). To date, four different isoforms of *PITX2* transcripts have been identified. *PITX2A* (271 amino acids), *PITX2B* (317 amino acids) and *PITX2C* (324 amino acids) contain three α helices of 60-amino acid homeodomain but differ at their amino-termini while *PITX2D* (205 amino acids) lacks most of the homeodomain and entire amino terminus (Cox et al., 2002). *PITX2A* and *PITX2B* are generated by alternative splicing, whereas *PITX2C* and *PITX2D* are produced using the internal promoter. All isoforms share identical carboxy termini containing conserved 14-amino acid OAR,

otp, aristaless and rax-homology domains (Cox et al., 2002). The activities of *PITX2* isoforms have been shown to be promoter- and cell-specific (Ganga et al., 2003; Schweickert, Campione, Steinbeisser, & Blum, 2000).

In humans, *PITX2* has been identified as a causative gene for an autosomal-dominant Axenfeld-Rieger syndrome type 1 (ARS, OMIM #180500). ARS has heterogeneous phenotypes mainly characterised by abnormal development of the anterior segment of the eye, craniofacial dysmorphism, dental abnormalities and redundant periumbilical skin (Amendt, Semina, & Alward, 2000; Hjalt & Semina, 2005; Tumer & Bach-Holm, 2009). *PITX2* mutations also link to anterior

segment dysgenesis 4 (OMIM #137600) (Gould & John, 2002) and non-syndromic eye abnormalities, the ring dermoid of cornea (OMIM #180550) (Xia et al., 2004), but have never been found to cause non-syndromic orodental anomalies.

Pitx2 is considered to be one of the earliest markers exclusively expressed in dental epithelium during tooth development (Hjalt et al., 2000; Mucchielli et al., 1997). It has been associated with several genes and transcriptional factors to pattern the dentition and initiate tooth formation (Amen et al., 2007; St.Amand et al., 2000). *Pitx2* null mice had arrested tooth development at the placode or bud stage, indicating that *Pitx2* has crucial roles in murine tooth development

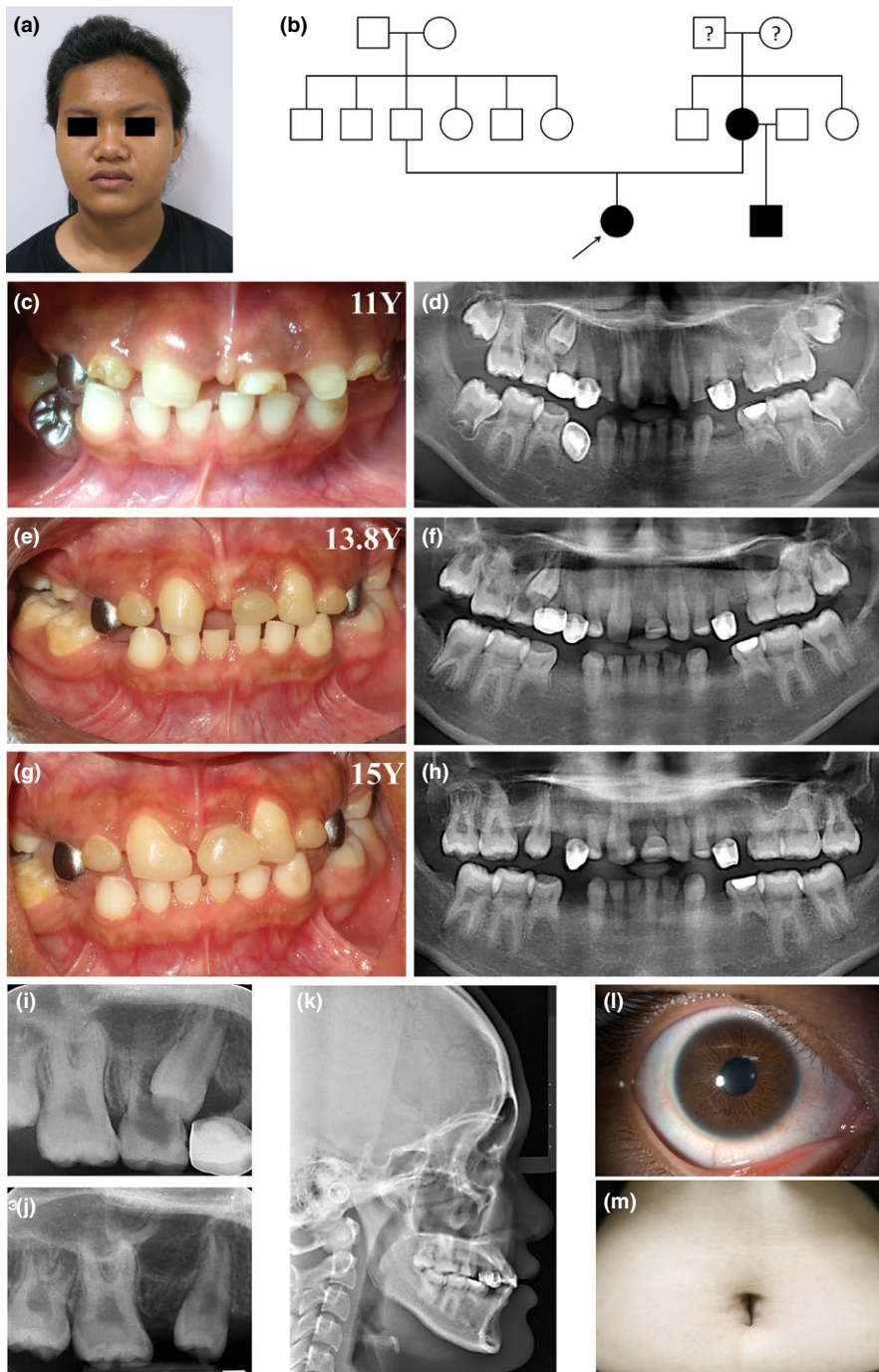


FIGURE 1 Clinical and radiographic phenotypes of the proband and family pedigree. (a) Facial photograph of the proband at age 15 years. (b) Pedigree of the family. The arrow marks the proband. (c–h) Intraoral photographs and panoramic radiographs of the proband showed only eleven permanent teeth including four-first molars, four-second molars, two maxillary central incisors and one maxillary right first premolar, retained primary teeth, peg-shaped central incisors, taurodont molars and unilateral posterior crossbite and midline diastema. (i) Periapical radiographs showed hypotaurodontism of the maxillary first molar. (j) The permanent maxillary right first premolar was erupting. (k) Lateral cephalometric radiograph revealed class III malocclusion and proclined maxillary incisors. (l) Ocular photograph of the right eye did not show any defects. (m) Periumbilical skin was unremarkable [Colour figure can be viewed at wileyonlinelibrary.com]

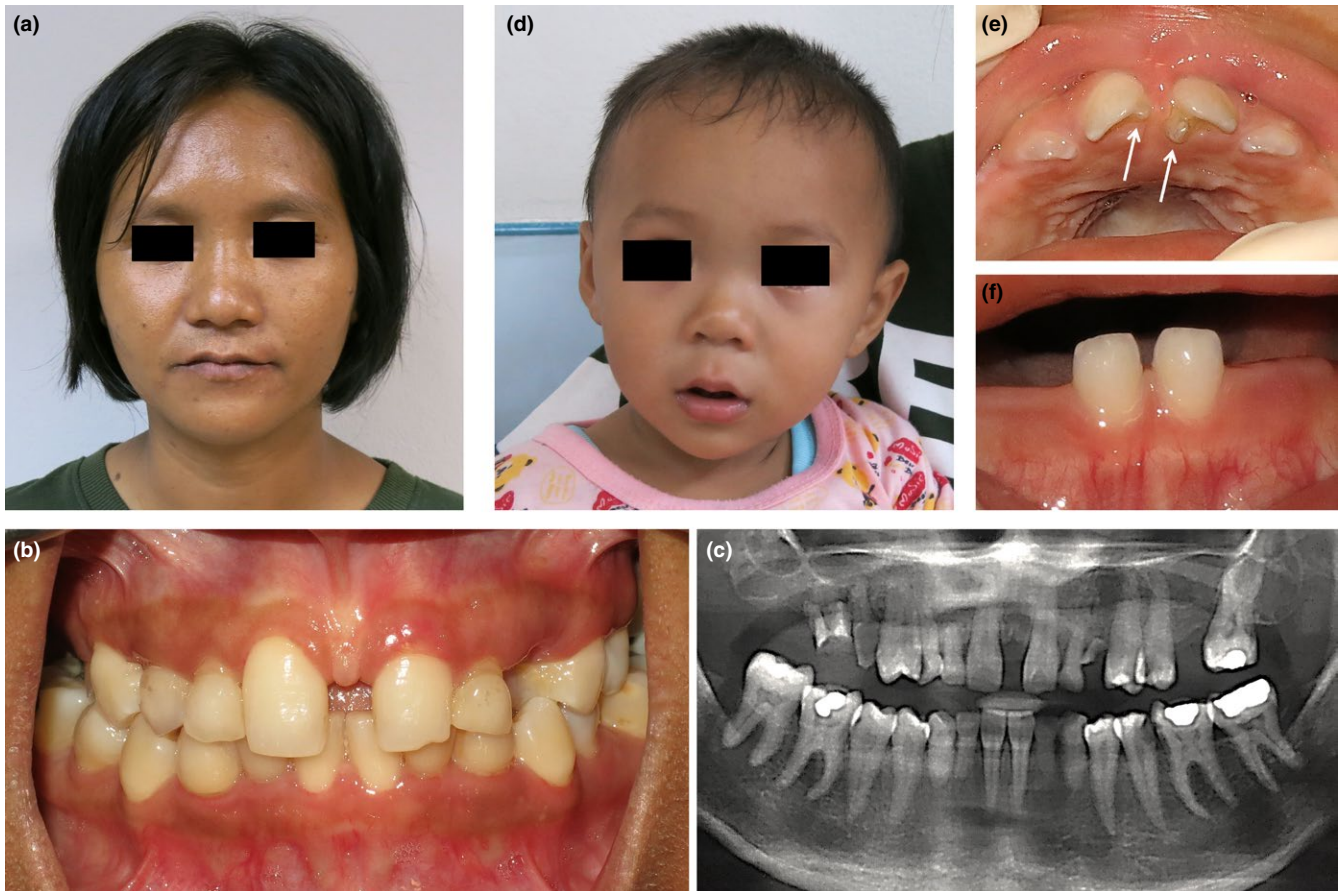

FIGURE 2 Clinical and radiographic phenotypes of the proband's mother and half-brother. (a) Frontal photograph of the mother at age 34 years. (b,c) Intraoral photograph and panoramic radiograph showed an absence of fourteen permanent teeth including four lateral incisors, four canines, maxillary left first molar, maxillary right second molar and four-third molars. Taurodontism and pulp stones were observed in the molars. High attached frenum with nodules and diastema were observed in the maxillary midline. (d) Facial photograph of the half-brother at age 14 months. (e-f) Intraoral photograph showed six primary teeth. The maxillary central incisors with talon cusps (arrows), high frenum attachment with nodules and midline diastema were observed [Colour figure can be viewed at wileyonlinelibrary.com]

(Gage, Suh, & Camper, 1999; Lin et al., 1999). However, the role of *PITX2* in human dentition has never been demonstrated.

Although the basis of tooth development has been broadly studied, the knowledge of isolated orodontal anomalies remains limited. This study reveals a novel heterozygous frameshift deletion, c.573_574delCA, p.L193QfsX5, in the exon 5 of *PITX2* gene segregating with unique orodontal anomalies in affected family members. Here, we identify for the first time that a novel mutation in the C-terminal domain of the *PITX2* gene is exclusively associated with non-syndromic orodontal anomalies.

2 | MATERIALS AND METHODS

2.1 | Recruitment of the family

A Thai family with three affected members was recruited for genetic studies. The study was exempted from review by the Institutional Review Board, Faculty of Medicine, Chulalongkorn University (IRB No. 311/60, Date of Exemption: 6 June 2017). Clinical and radiographic

examinations and blood collection were performed with the understanding and written consent of each participant according to the Declaration of Helsinki.

2.2 | Whole-exome sequencing and bioinformatics

Genomic DNA was extracted from peripheral blood leucocytes and sent to Macrogen, Inc. (Seoul, Korea). The DNA sample was prepared as an Illumina sequencing library. The sequencing libraries were enriched by SureSelect Human All Exon V5 (Agilent Technologies, Santa Clara, CA) and was sequenced onto Hiseq 4000 (Illumina, San Diego, CA). The raw data per exome were mapped to the human reference genome hg19 using Burrows–Wheeler Aligner. Variant calling was performed using GATK with HaplotypeCaller. Finally, SNVs and indels were annotated using SnpEff and annotation databases, dbpSNP 142, 1000Genome, ClinVar and ESP. The variants were subsequently filtered out if they were present in our in-house database of 700 unrelated Thai exomes. The variants would be called novel if they were not listed in the Human Gene Mutation Database (www.hgmd.cf.ac).


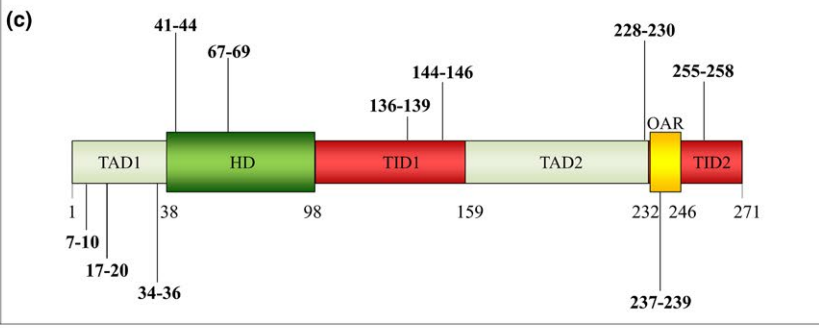
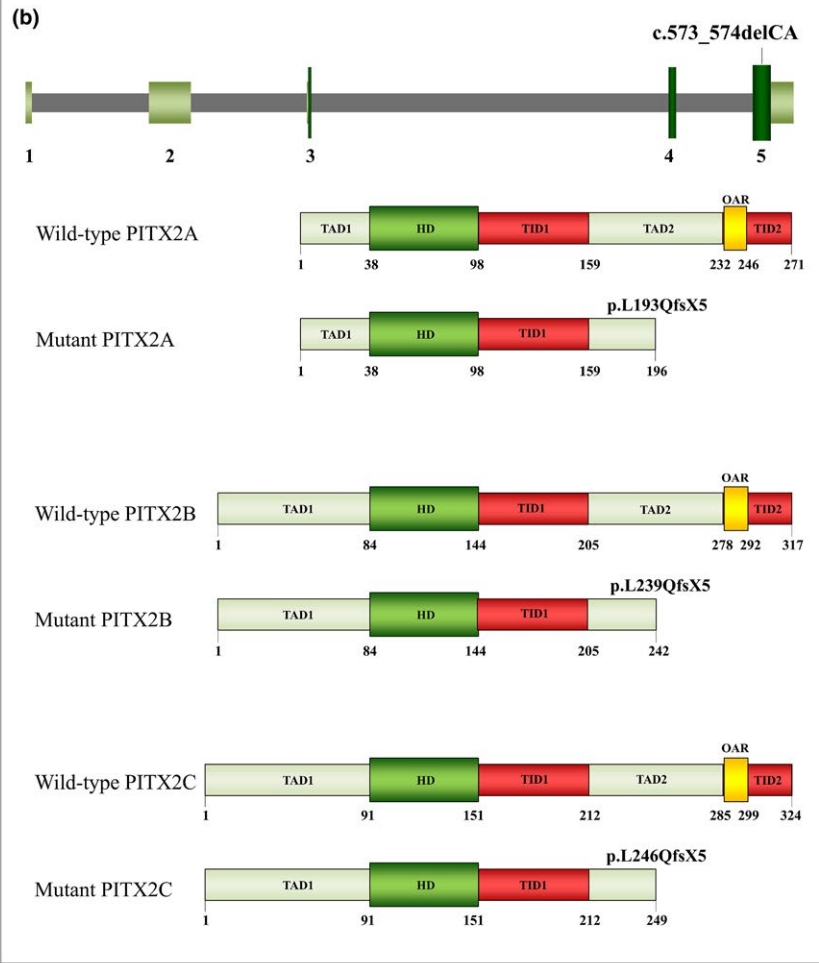
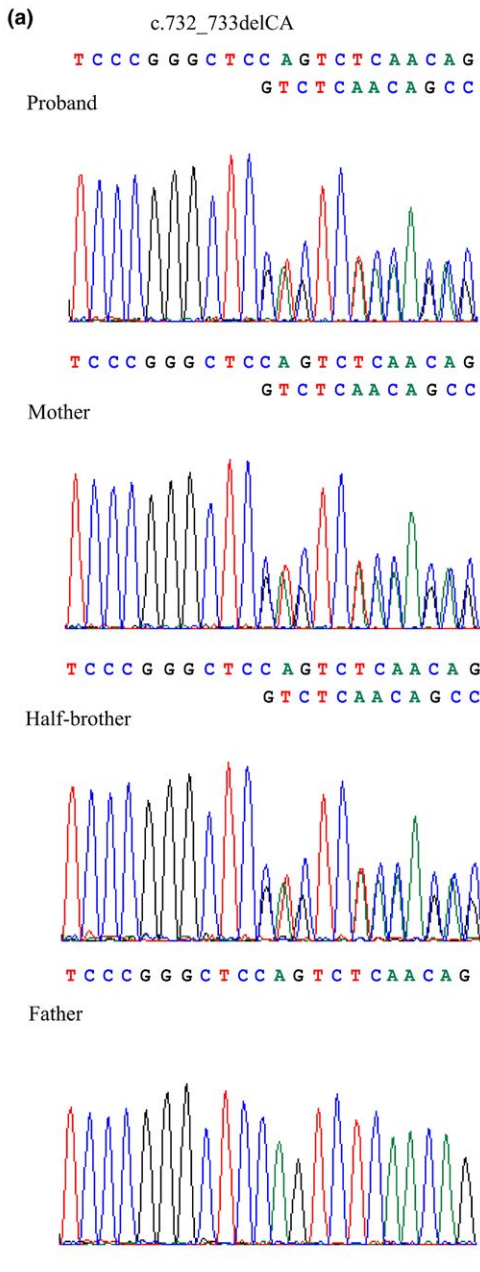


FIGURE 3 Genetic analyses of the family. (a) Sequence chromatograms demonstrated the presence of novel heterozygous frameshift deletion, c.573_574delCA, p.L193QfsX5, in exon 5 of the *PITX2A* gene (NM_153427.2) in the proband, mother and half-brother. The father did not possess the mutation. (b) Schematic diagrams of the *PITX2A* gene (NM 153427.2) and the structural domains of wild-type and mutant PITX2 proteins. The mutation was indicated above the structural domains of the mutant PITX2 proteins. PITX2A (NP_700476.1); PITX2B (NP_700475.1); PITX2C (NP_000316.2); TAD1, transcriptional activation domain 1; HD, homeodomain; TID1, transcriptional inhibitory domain 1; TAD2, transcriptional activation domain 2; TID2, transcriptional inhibitory domain 2. (c) Schematic diagram of PITX2 showed the sites of protein kinase C shown by amino acid numbers in bold. (d) Sequence alignment of partial amino acid sequence of PITX2 among several human PITX2 isoforms and different species. Conservation of the codon 193–196 of PITX2A across species was indicated by a red bar. The arrowhead indicated the localisation of p.L193 [Colour figure can be viewed at wileyonlinelibrary.com]

uk/ac/index.php) and the Exome Aggregation Consortium database (exac.broadinstitute.org). The amino acid sequence of human PITX2A (NP_700476.1) was compared with those of the human PITX2B (NP_700475.1), human PITX2C (NP_000316.2), rhesus monkey PITX2 X1 (XP_001091288.1), mouse PITX2A (NP_001035969.1), cattle PITX2 (NP_001091460.1), dog PITX2 X1 (XP_851370), tropical clawed frog PITX2 (NP_001017227.1) and zebrafish PITX2 (NP_571050.1).

2.3 | Mutation validation

The variants were confirmed, and segregation analysis was performed by polymerase chain reaction (PCR) and Sanger sequencing. DNA of the proband's parents and half-brother was also Sanger-sequenced to search for the mutation. The coding region of *PITX2* was amplified with primers: PITX2F: TGGAGTGTCTTTGCTTTC and PITX2R: CAGGCCGAGCTATGCAAGAA. The PCR products were treated with ExoSAP-IT (USP Corporation, Cleveland, OH) and sent for direct sequencing at Macrogen. Sequence data were analysed using Sequencher (V.5.0; Gene Codes Corporation, Ann Arbor, MI).

3 | RESULTS

3.1 | Clinical and radiographic investigations

The proband was a 15-year-old girl (Figure 1a). She was delivered naturally at 35 weeks of gestation. Her birthweight was 2,350 g (<3rd centile). Her parents were non-consanguineous and healthy (Figure 1b). Family medical history was unremarkable. At the age of 11 years, the proband presented for dental treatment at the Faculty of Dentistry, Chulalongkorn University, Thailand. She was concerned of her small front teeth. Initial oral examination revealed generalised anterior spacing, absence of multiple permanent teeth, retained primary teeth, malocclusion, enamel hypoplasia and dental caries. Seventeen primary teeth were present. Two primary maxillary canines and two primary first molars were restored with stainless steel crowns. Her labial frenum showed nodule at the alveolar third. Oral soft tissues including gingiva, oral mucosa, tongue and oropharynx were unremarkable (Figure 1c). Radiographic examinations revealed peg-shaped maxillary central incisors, taurodont molars and absence of twenty-one permanent teeth including four canines, four lateral incisors, two mandibular central incisors, three-first premolars, four-second premolars and four-third molars (Figure 1d). An initial treatment included composite restorations on her anterior teeth for aesthetic improvement. All

posterior teeth were fissure-sealed. Regular recall and special monitoring of craniofacial development were implemented.

At 13.8 years of age, the primary maxillary right first and second molars were extracted due to extensive root resorption and to facilitate the eruption of the first premolar. Periapical radiograph showed hypotaurodontism of the permanent maxillary first molar (Figure 1e,f,i,j).

At age 15 years, the orthodontic analysis of the proband demonstrated skeletal class III malocclusion, unilateral posterior crossbite and proclined maxillary incisors (Figure 1g,h,k). Her weight was 56 kg (50th–75th centile) and her height was 156 cm (10th–25th centile). She had normal intelligence. Ophthalmic examination detected short-sightedness (−0.87 for the right eye, −0.25 for the left eye) and astigmatism (−1.87 for the right eye, −2.00 for the left eye). Iris hypoplasia was not observed. No abnormalities were found in the anterior and posterior chambers of both eyes (Figure 1l). The umbilical skin was unremarkable (Figure 1m). No other medical abnormalities were detected.

Orofacial investigations of the proband's mother at age 34 years showed similar phenotypes to the proband including oligodontia, retained primary teeth, taurodontism, peg-shaped maxillary central incisors, labial frenum with nodule and midline diastema. Fourteen permanent teeth including four lateral incisors, four canines, maxillary left first molar, maxillary right second molar and four-third molars were absent. Four primary lateral incisors and four canines were retained. The molars developed pulp stones (Fig 2a–c). The half-brother of the proband at age 14 months had six primary teeth. His maxillary central incisors had talon cusps. He also had labial frenum with nodule and midline diastema, similar to the proband and his mother (Figure 2d–f). Medical examinations of the proband's mother, half-brother and father were unremarkable.

3.2 | Genetic investigation

Mutation analysis was performed by whole-exome sequencing (WES). The total yield of 6,180,666,518 bp was achieved. The capture efficiency varied across the target with 95.5% was more than 10X, and the mean read depth of target regions was 75.6X. To identify potential pathogenic variants, the variants were filtered out if they were (a) coverage <10X; (b) quality score <20; (c) non-coding variants and synonymous exonic variants; and (d) minor allele frequency $\geq 1\%$ in the database of SNPs, 1000 Genomes Project Consortium, Exome Variant Server, and our in-house database of 700 unrelated Thai exomes. After filtering, we looked for variants located in the coding regions of known genes associated with tooth agenesis for all potential

pathogenic SNVs and indels. It was found that the proband harboured a novel heterozygous frameshift deletion, c.573_574delCA, p.L193QfsX5, in the *PITX2A* gene (NM_153427.2), corresponding to the c.711_712delCA, p.L239QfsX5 in *PITX2B* (NM_153426) and c.732_733delCA, p.L246QfsX5 in *PITX2C* (NM_000325.5). The mutation was absent in HGMD[®], ExAC and our in-house database of 700 unrelated Thai exomes. The variants were confirmed by PCR and Sanger sequencing. The DNA of her parents and half-brother was also Sanger-sequenced. We detected the mutation in the proband's mother and half-brother, corresponding to orodental phenotypes (Figure 3a). The p.L193QfsX5 mutation changed leucine to glutamine at codon 193, creating a new reading frame in the transcriptional activation domain 2 (TAD2) and inserting a premature stop codon at codon 197 of PITX2 protein. The mutant protein had truncated C-terminal tail and contained 196 amino acids compared to 271 of wild-type PITX2A (Figure 3b). The deleted part contained three sites of protein kinase C (Figure 3c). The altered amino acids were highly conserved among different human PITX2 isoforms and species including rhesus monkey, mouse, cattle, dog, tropical clawed frog and zebrafish (Figure 3d).

4 | DISCUSSION

We have identified a Thai family with distinct non-syndromic orodental anomalies inherited as an autosomal-dominant trait. Oral phenotypes of the affected individuals include oligodontia specifically all permanent lateral incisors and canines, taurodont molars, peg-shaped maxillary central incisors, high attachment of the labial frenum with nodule and midline diastema.

Despite the high prevalence of dental anomalies particularly tooth agenesis, which has been reported up to 20 percentage, there are still a restricted number of mutations in known genes including *MSX1*, *PAX9*, *EDA*, *AXIN2*, *LTBP3* and *WNT10A* associated with isolated tooth agenesis (van den Boogaard et al., 2012; Nieminen, 2009). As our patients had heterogeneous orodental anomalies, we selected WES to identify pathogenic variants in the proband. Using WES, we were able to detect a novel heterozygous frameshift deletion, c.573_574delCA, p.L193QfsX5, in exon 5 of the *PITX2A* gene. Sanger sequencing identified the mutation segregating in affected family members. The p.L193QfsX5 mutation occurred in the middle region of TAD2 of PITX2. It introduced a premature stop codon resulting in the truncated mutant protein containing 196 amino acids compared to 271 amino acids of wild-type PITX2A (Figure 3b). The altered amino acids were all conserved among human PITX2 isoforms and several species indicating that these regions are functionally important (Figure 3d).

In humans, *PITX2* mutations have predominantly been found in ARS patients presenting anomalies of the eyes, teeth and abdomen. The majorities of *PITX2* mutations were missense clustering in the DNA-binding homeodomain, whereas splice site, frameshift and nonsense mutations were found throughout the gene (Reis et al., 2012; Tumer & Bach-Holm, 2009). The relationship between localisation of *PITX2* mutations and disease severity has not been elucidated. The

p.L193QfsX5 mutation in the TAD2 in the PITX2 C-terminus, to our knowledge, is the only mutation in the *PITX2* gene associated with human non-syndromic orodental anomalies. Protein-truncating mutations in the C-terminus demonstrated various effects on PITX2 activity (Footz, Idrees, Acharya, Kozlowski, & Walter, 2009; Saadi et al., 2006). While the N-terminal domain of *Pitx2* did not play a significant role in tooth development (Kiousi et al., 2002), the C-terminal tail was shown to modulate DNA binding, transactivation and protein interactions important for correct gene function (Amendt, Sutherland, & Russo, 1999; Saadi et al., 2006). To date, a small number of mutations have been reported in the C-terminus of PITX2. Nonsense mutations observed in the TAD2 domain showed alteration in a large numbers of amino acids associated with the full spectrum of ARS (Perveen et al., 2000). Three further C-terminal deletions introducing a premature stop codon in the OAR domain were all linked to the full spectrum of ARS (Borges et al., 2002; Brooks et al., 2004; Vieira et al., 2006). Interestingly, the heterozygosity for R62H mutation in the DNA-binding homeodomain of the *PITX2* gene was associated with isolated ocular anomalies, the ring dermoid of the cornea (Xia et al., 2004). These postulate that the particular mutations in the different regions of *PITX2* could cause distinct phenotypes.

Gene dosage was proposed to account for the severity of ARS and differential organ development seen in *Pitx2* heterozygous and homozygous mice (Gage et al., 1999; Kozlowski & Walter, 2000; Maciolek, Alward, Murray, Semina, & McNally, 2006). Allelic combinations of *Pitx2* showed that the magnitude of tooth morphogenesis was correlated with total *Pitx2* dose (Liu, Selever, Lu, & Martin, 2003). Consistently, ocular malformations were milder when the mutant proteins retained partial function of PITX2 compared to those of non-function protein (Kozlowski & Walter, 2000). Based on these evidences, the p.L193QfsX5 mutation which changed only five amino acids and created a premature stop codon within the TAD2 domain of PITX2 might only have minor effect on the protein function and specifically cause isolated orodental anomalies in our family.

In addition, the p.L193QfsX5 mutation disturbed three PKC sites and OAR domain in the C-terminus of PITX2 (Figure 3c). Previous study showed that the deletion of three PKC sites in the C-terminal tail and OAR domain decreased transcriptional activation and C-terminal phosphorylation positively regulated the transcriptional activity of PITX2 (Espinoza et al., 2005). These suggest that our mutation could disturb PKC phosphorylation and transcriptional activity of PITX2 by haploinsufficiency and the disruption of PITX2 functions is specifically related to tooth development, while maintaining other wild-type activities.

Dlx2 plays a vital role in morphogenesis of the proximal first and second branchial arches (Qiu et al., 1995). Interestingly, the p.R84W mutation in *PITX2*, shown to activate the *Dlx2* promoter, was associated with ARS without tooth anomalies, whereas p.T68P mutation, unable to transactivate the *Dlx2* promoter, presented the full spectrum of ARS (Espinoza, Cox, Semina, & Amendt, 2002). These suggest molecular mechanisms for tooth development involving *Dlx2* gene expression in ARS patients. Further functional investigations on the effect of p.L193QfsX5 mutation on *Dlx2* activation

will be useful to clarify its specific molecular mechanism in tooth development.

The findings of isoform deletions of *Pitx2* revealed interchangeable functions between isoforms in tooth morphogenesis (Liu et al., 2003). All *PITX2* mutations associated with ARS were consistently found in common regions among isoforms (Reis et al., 2012; Tumer & Bach-Holm, 2009). These exclude the specific requirement of each isoform to regulate target pathways or the formation of *Pitx2* isoform heterodimers in tooth development. Notably, the p.L193QfsX5 mutation was located in the C-terminus of *PITX2* shared by all isoforms (Figure 3b). These suggest that the existence of different *PITX2* isoforms would not influence the phenotypes of our patients.

In conclusion, we have successfully identified a novel heterozygous frameshift deletion, c.573_574delCA, p.L193QfsX5, in the exon 5 of *PITX2* segregating with orodontal anomalies in the affected members of a family. This is the first study demonstrating that the *PITX2* mutation is related to non-syndromic orodontal anomalies in humans. The study expands the *PITX2* mutation spectrum and highlights the role of the C-terminal domain of *PITX2* in tooth development.

ACKNOWLEDGEMENTS

This study was supported by the Thailand Research Fund (TRF) and Office of Higher Education Commission (OHEC) Thailand (MRG6080001), the Faculty of Dentistry, Chulalongkorn University (DRF60007), the Chulalongkorn Academic Advancement Into Its 2nd Century Project, and the Rachadapisek Sompot Fund for Postdoctoral Fellowship, Chulalongkorn University. We thank Dr Worawalun Honglertrapakul, an ophthalmologist for providing a thorough eye examination for the patients.

AUTHOR CONTRIBUTIONS

N. Intarak contributed to conception, data analysis and drafting the manuscript; T. Theerapanon contributed to data analysis and drafting the manuscript; C. Ittiwut contributed to data acquisition and interpretation; K. Suphapeetiporn contributed to critical revision of the manuscript; V. Shotelersuk contributed to conception, performing physical examination and critical revision of the manuscript; T. Porntaveetus contributed to data acquisition and analysis, drafting and critical revision of the manuscript. All authors gave final approval and agree to be accountable for all aspects of the work.

CONFLICT OF INTEREST

None to declare.

ORCID

K Suphapeetiporn  <http://orcid.org/0000-0001-5679-7547>

T Porntaveetus  <http://orcid.org/0000-0003-0145-9801>

REFERENCES

- Amen, M., Liu, X., Vadlamudi, U., Elizondo, G., Diamond, E., Engelhardt, J. F., & Amendt, B. A. (2007). *PITX2* and beta-catenin interactions regulate Lef-1 isoform expression. *Molecular and Cellular Biology*, 27(21), 7560–7573. <https://doi.org/10.1128/MCB.00315-07>
- Amendt, B. A., Semina, E. V., & Alward, W. L. M. (2000). Rieger syndrome: A clinical, molecular, and biochemical analysis. *Cellular and Molecular Life Sciences*, 57(11), 1652–1666. <https://doi.org/10.1007/PL00000647>
- Amendt, B. A., Sutherland, L. B., & Russo, A. F. (1999). Multifunctional role of the *Pitx2* homeodomain protein C-terminal tail. *Molecular and Cellular Biology*, 19(10), 7001–7010. <https://doi.org/10.1128/MCB.19.10.7001>
- van den Boogaard, M. J., Creton, M., Bronkhorst, Y., van der Hout, A., Hennekam, E., Lindhout, D., ... Ploos van Amstel, H. K. (2012). Mutations in *WNT10A* are present in more than half of isolated hypodontia cases. *Journal of Medical Genetics*, 49(5), 327–331. <https://doi.org/10.1136/jmedgenet-2012-100750>
- Borges, A. S., Susanna, R. Jr, Carani, J. C., Betinjane, A. J., Alward, W. L., Stone, E. M., ... Nishimura, D. Y. (2002). Genetic analysis of *PITX2* and *FOXC1* in Rieger Syndrome patients from Brazil. *Journal of Glaucoma*, 11(1), 51–56. <https://doi.org/10.1097/00061198-200202000-00010>
- Brooks, B. P., Moroi, S. E., Downs, C. A., Wiltse, S., Othman, M. I., Semina, E. V., & Richards, J. E. (2004). A novel mutation in the *PITX2* gene in a family with Axenfeld-Rieger syndrome. *Ophthalmic Genetics*, 25(1), 57–62. <https://doi.org/10.1076/opge.25.1.57.29002>
- Cox, C. J., Espinoza, H. M., McWilliams, B., Chappell, K., Morton, L., Hjalt, T. A., ... Amendt, B. A. (2002). Differential regulation of gene expression by *PITX2* isoforms. *Journal of Biological Chemistry*, 277(28), 25001–25010. <https://doi.org/10.1074/jbc.M201737200>
- Espinoza, H. M., Cox, C. J., Semina, E. V., & Amendt, B. A. (2002). A molecular basis for differential developmental anomalies in Axenfeld-Rieger syndrome. *Human Molecular Genetics*, 11(7), 743–753. <https://doi.org/10.1093/hmg/11.7.743>
- Espinoza, H. M., Ganga, M., Vadlamudi, U., Martin, D. M., Brooks, B. P., Semina, E. V., ... Amendt, B. A. (2005). Protein kinase C phosphorylation modulates N- and C-terminal regulatory activities of the *PITX2* homeodomain protein. *Biochemistry*, 44(10), 3942–3954. <https://doi.org/10.1021/bi048362x>
- Footz, T., Idrees, F., Acharya, M., Kozlowski, K., & Walter, M. A. (2009). Analysis of mutations of the *PITX2* transcription factor found in patients with Axenfeld-Rieger syndrome. *Investigative Ophthalmology & Visual Science*, 50(6), 2599–2606. <https://doi.org/10.1167/iov.08-3251>
- Gage, P. J., Suh, H., & Camper, S. A. (1999). Dosage requirement of *Pitx2* for development of multiple organs. *Development*, 126(20), 4643–4651.
- Ganga, M., Espinoza, H. M., Cox, C. J., Morton, L., Hjalt, T. A., Lee, Y., & Amendt, B. A. (2003). *PITX2* isoform-specific regulation of atrial natriuretic factor expression: Synergism and repression with *Nkx2.5*. *Journal of Biological Chemistry*, 278(25), 22437–22445. <https://doi.org/10.1074/jbc.M210163200>
- Gould, D. B., & John, S. W. (2002). Anterior segment dysgenesis and the developmental glaucomas are complex traits. *Human Molecular Genetics*, 11(10), 1185–1193. <https://doi.org/10.1093/hmg/11.10.1185>
- Hjalt, T. A., & Semina, E. V. (2005). Current molecular understanding of Axenfeld-Rieger syndrome. *Expert Reviews in Molecular Medicine*, 7(25), 1–17. <https://doi.org/10.1017/S1462399405010082>
- Hjalt, T. A., Semina, E. V., Amendt, B. A., & Murray, J. C. (2000). The *Pitx2* protein in mouse development. *Developmental Dynamics*, 218(1), 195–200. [https://doi.org/10.1002/\(SICI\)1097-0177\(200005\)218:1<195::AID-DVDY17>3.0.CO;2-C](https://doi.org/10.1002/(SICI)1097-0177(200005)218:1<195::AID-DVDY17>3.0.CO;2-C)
- Kioussi, C., Briata, P., Baek, S. H., Rose, D. W., Hamblet, N. S., Herman, T., ... Rosenfeld, M. G. (2002). Identification of a *Wnt/Dvl/beta-Catenin* → *Pitx2* pathway mediating cell-type-specific proliferation during development. *Cell*, 111(5), 673–685. [https://doi.org/10.1016/S0092-8674\(02\)01084-X](https://doi.org/10.1016/S0092-8674(02)01084-X)



- Kozlowski, K., & Walter, M. A. (2000). Variation in residual PITX2 activity underlies the phenotypic spectrum of anterior segment developmental disorders. *Human Molecular Genetics*, 9(14), 2131–2139. <https://doi.org/10.1093/hmg/9.14.2131>
- Lin, C. R., Kioussi, C., O'Connell, S., Briata, P., Szeto, D., Liu, F., ... Rosenfeld, M. G. (1999). Pitx2 regulates lung asymmetry, cardiac positioning and pituitary and tooth morphogenesis. *Nature*, 401(6750), 279–282. <https://doi.org/10.1038/45803>
- Liu, W., Selever, J., Lu, M. F., & Martin, J. F. (2003). Genetic dissection of Pitx2 in craniofacial development uncovers new functions in branchial arch morphogenesis, late aspects of tooth morphogenesis and cell migration. *Development*, 130(25), 6375–6385. <https://doi.org/10.1242/dev.00849>
- Maciolek, N. L., Alward, W. L., Murray, J. C., Semina, E. V., & McNally, M. T. (2006). Analysis of RNA splicing defects in PITX2 mutants supports a gene dosage model of Axenfeld-Rieger syndrome. *BMC Medical Genetics*, 7, 59. <https://doi.org/10.1186/1471-2350-7-59>
- Mucchielli, M. L., Mitsiadis, T. A., Raffo, S., Brunet, J. F., Proust, J. P., & Goridis, C. (1997). Mouse Otlx2/RIEG expression in the odontogenic epithelium precedes tooth initiation and requires mesenchyme-derived signals for its maintenance. *Developmental Biology*, 189(2), 275–284. <https://doi.org/10.1006/dbio.1997.8672>
- Nieminen, P. (2009). Genetic basis of tooth agenesis. *Journal of Experimental Zoology Part B: Molecular and Developmental Evolution*, 312b(4), 320–342. <https://doi.org/10.1002/jez.b.21277>
- Perveen, R., Lloyd, I. C., Clayton-Smith, J., Churchill, A., van Heyningen, V., Hanson, I., ... Black, G. C. (2000). Phenotypic variability and asymmetry of Rieger syndrome associated with PITX2 mutations. *Investigative Ophthalmology & Visual Science*, 41(9), 2456–2460.
- Qiu, M., Bulfone, A., Martinez, S., Meneses, J. J., Shimamura, K., Pedersen, R. A., & Rubenstein, J. L. (1995). Null mutation of Dlx-2 results in abnormal morphogenesis of proximal first and second branchial arch derivatives and abnormal differentiation in the forebrain. *Genes & Development*, 9(20), 2523–2538. <https://doi.org/10.1101/gad.9.20.2523>
- Reis, L. M., Tyler, R. C., Volkmann Kloss, B. A., Schilter, K. F., Levin, A. V., Lowry, R. B., ... Semina, E. V. (2012). PITX2 and FOXC1 spectrum of mutations in ocular syndromes. *European Journal of Human Genetics*, 20(12), 1224–1233. <https://doi.org/10.1038/ejhg.2012.80>
- Saadi, I., Toro, R., Kuburas, A., Semina, E., Murray, J. C., & Russo, A. F. (2006). An unusual class of PITX2 mutations in Axenfeld-Rieger syndrome. *Birth Defects Research. Part A, Clinical and Molecular Teratology*, 76(3), 175–181. <https://doi.org/10.1002/bdra.20226>
- Schweickert, A., Campione, M., Steinbeisser, H., & Blum, M. (2000). Pitx2 isoforms: Involvement of Pitx2c but not Pitx2a or Pitx2b in vertebrate left-right asymmetry. *Mechanisms of Development*, 90(1), 41–51. [https://doi.org/10.1016/S0925-4773\(99\)00227-0](https://doi.org/10.1016/S0925-4773(99)00227-0)
- Semina, E. V., Reiter, R., Leysens, N. J., Alward, W. L., Small, K. W., Datson, N. A., ... Murray, J. C. (1996). Cloning and characterization of a novel bicoid-related homeobox transcription factor gene, RIEG, involved in Rieger syndrome. *Nature Genetics*, 14(4), 392–399. <https://doi.org/10.1038/ng1296-392>
- St.Amand, T. R., Zhang, Y., Semina, E. V., Zhao, X., Hu, Y., Nguyen, L., Murray, J. C., ... Chen, Y. (2000). Antagonistic signals between BMP4 and FGF8 Define the expression of Pitx1 and Pitx2 in mouse tooth-forming anlage. *Developmental Biology*, 217(2), 323–332. <https://doi.org/10.1006/dbio1999.9547>
- Tumer, Z., & Bach-Holm, D. (2009). Axenfeld-Rieger syndrome and spectrum of PITX2 and FOXC1 mutations. *European Journal of Human Genetics*, 17(12), 1527–1539. <https://doi.org/10.1038/ejhg.2009.93>
- Vieira, V., David, G., Roche, O., de la Houssaye, G., Boutboul, S., Arbogast, L., ... Abitbol, M. (2006). Identification of four new PITX2 gene mutations in patients with Axenfeld-Rieger syndrome. *Molecular Vision*, 12, 1448–1460.
- Xia, K., Wu, L., Liu, X., Xi, X., Liang, D., Zheng, D., ... Xia, J. (2004). Mutation in PITX2 is associated with ring dermoid of the cornea. *Journal of Medical Genetics*, 41(12), e129. <https://doi.org/10.1136/jmg.2004.022434>

How to cite this article: Intarak N, Theerapanon T, Ittiwut C, Suphapeetiporn K, Pornaveetus T, Shotelersuk V. A novel PITX2 mutation in non-syndromic orodental anomalies. *Oral Dis*. 2018;24:611–618. <https://doi.org/10.1111/odi.12804>