

## A CASE OF PFEIFFER SYNDROME TYPE 1 WITH AN A344P MUTATION IN THE *FGFR2* GENE

Vorasuk Shotelersuk<sup>1</sup>, Sumarlee Srivuthana<sup>1</sup>, Chupong Ittiwut<sup>2</sup>, Apiradee Theamboonlers<sup>3</sup>, Charan Mahatumarat<sup>4</sup> and Yong Poovorawan<sup>1</sup>

Departments of <sup>1</sup>Pediatrics, <sup>2</sup>Anatomy, <sup>4</sup>Surgery, Faculty of Medicine, Chulalongkorn University, Bangkok 10330, Thailand; <sup>3</sup>The Thai Red Cross, Bangkok 10330, Thailand

**Abstract.** Pfeiffer syndrome, an autosomal dominant disorder, consists of craniosynostosis, broadening of the thumbs and great toes, and partial soft tissue syndactyly of the hands and feet. Three clinical subtypes have been classified mainly for the purpose of genetic counseling. Mutations in *FGFR1* and *FGFR2* are known to be associated with the syndrome. However, the correlation between genotype and phenotype is not well defined. Only one patient with Pfeiffer syndrome with no other clinical information has been reported to have had an A344P mutation of the *FGFR2*. Here we report a Thai male patient with sporadic Pfeiffer syndrome type 1 with impaired intelligence (IQ = 77). Mutation analysis revealed A344P in *FGFR2*. Identification of the clinical features and molecular defects in more patients is required to better correlate the genotype and phenotype of this complex syndrome.

### INTRODUCTION

Pfeiffer syndrome (MIM 101600), an autosomal dominant disorder, consists of craniosynostosis, broadening of the thumbs and great toes, and partial soft tissue syndactyly of the hands and feet (Martsolf *et al*, 1971). Three clinical subtypes have been delineated by Cohen (1993). Patients with type 1 have the classical phenotype with normal to near normal intelligence. Affected individuals with type 2 have a cloverleaf skull, severe CNS involvement, and do poorly with early death. Type 3 is similar to type 2 with the absence of a cloverleaf skull. Most cases of Pfeiffer syndrome are sporadic. In familial cases, autosomal dominant inheritance with complete penetrance is characteristic. Variable expressivity has involved mostly the presence

and the degree of syndactyly (Cohen, 1993).

On the molecular level, Pfeiffer syndrome displays locus heterogeneity. The first gene identified to be responsible for the syndrome was *FGFR1* (MIM 136350) (Muenke *et al*, 1994). A year later, a second locus, *FGFR2* (MIM 176943), was found (Schell *et al*, 1995). At least 24 different mutations in *FGFR2* associated with the Pfeiffer phenotype have been characterized (Passos-Bueno *et al*, 1999). Some mutations have been reported to cause a specific clinical type such as Ser351Cys which was found in a patient with Pfeiffer syndrome type 3 (Gripp *et al*, 1998). Only one patient with Pfeiffer syndrome has been reported to have an A344P mutation of the *FGFR2* (Meyers *et al*, 1996). No other information about this patient was given. Identification of the clinical features and molecular defects in more patients is required to better correlate the genotype and phenotype of this complex syndrome.

Here we report a Thai male patient with sporadic Pfeiffer syndrome type 1 with impaired intelligence. Mutation analysis revealed A344P in *FGFR2*. He represents the second

---

Correspondence: Dr Vorasuk Shotelersuk, Head, Division of Genetics, and Metabolism, Department of Pediatrics, Sor Kor Building 11<sup>th</sup> floor, King Chulalongkorn Memorial Hospital, Bangkok 10330, Thailand.

Tel: 662-256-4989; Fax: 662-256-4911  
E-mail: fmedvst@md2.md.chula.ac.th



case of this mutation reported to date.

## MATERIALS AND METHODS

### Case report

A male patient was born at term to a 41-year-old G2P1 Thai mother and a 40-year-old unrelated Thai father. Prenatal history was unremarkable. A cesarean section was performed because of premature rupture of membranes. Birth weight was 3400 g (75<sup>th</sup> centile), birth length 51 cm (75<sup>th</sup> centile), and head circumference 37 cm (>90<sup>th</sup> centile). Physical examination at 4 months of age revealed bicoronal synostosis, proptosis, midface hypoplasia, micrognathia, and enlarged great toes. A diagnosis of Pfeiffer syndrome was given. The patient underwent frontoorbital advancement at 7 months old. The patient had obstructive sleep apnea requiring adenoidectomy and uvuloplasty at 1½ years old. His IQ at 3 years and 2 months old was 77. His last clinic visit was at 6 years of age (Fig 1). At this time his height was 108 cm (25<sup>th</sup> centile), his weight 15 kg (10<sup>th</sup> centile), and his head circumference 50.5 cm (between 10<sup>th</sup> and 25<sup>th</sup> centile). Turribrachycephaly, proptosis, and midface hypoplasia were noted. His thumbs were slightly broadened. The great toe/second toe ratios were 1.96 on the right and 1.74 on the left. The physical features of his parents and brother revealed no major malformations.

### Mutation analysis

After informed consent was obtained in accordance with the standards set by local institutional review boards, six ml of peripheral blood was obtained for DNA isolation by a standard method. *FGFR1* exon 5, *FGFR2* exon 8, and *FGFR2* exon 10 were PCR amplified. Primers, annealing temperatures and PCR product sizes are shown in Table 1. The PCR products were electrophoresed on a 2% agarose gel (Promega) and stained with ethidium bromide. The visualized band was extracted and purified with a kit (Bio 101), and sequenced in both directions by using an automated DNA sequencer (ABI Prism 310 Genetic

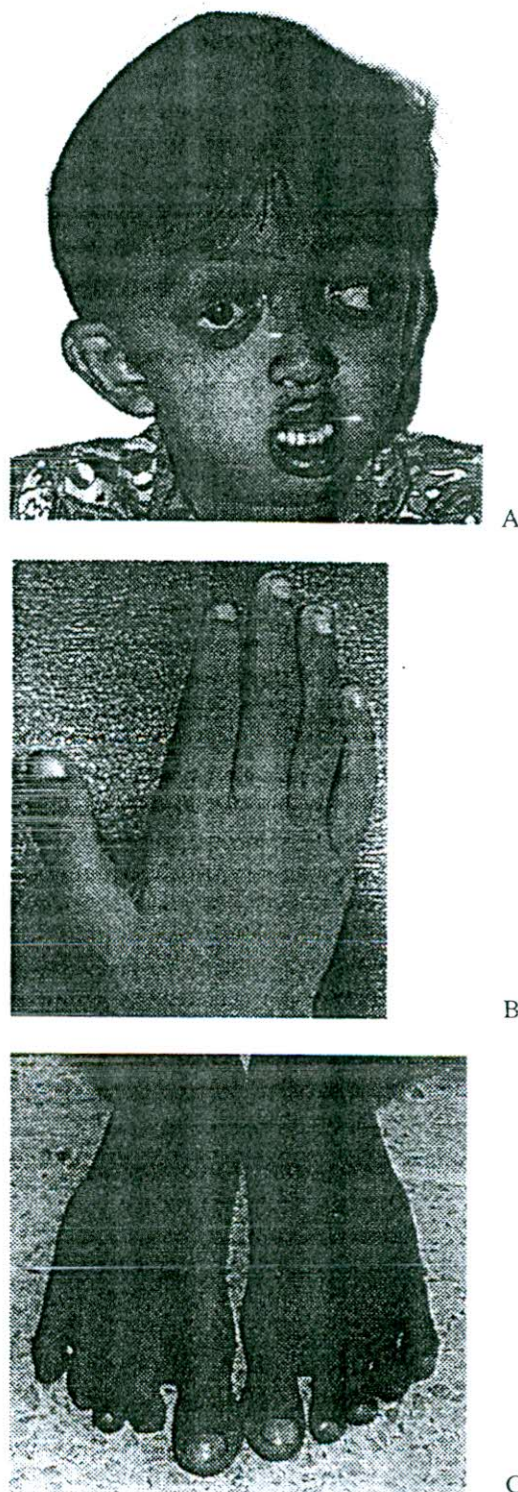


Fig 1—A. Face B. Right hand C. Feet of the patient.

